



**RESENTING CLINICAL SIGNS**

History: Pre-op ECG showed a left axis deviation and supraventricular arrhythmia.

DATE

**ECHOCARDIOGRAPHIC FINDINGS**

9/21/21

2D, M-mode, and Doppler study.

PERFORMED BY:

Left atrial size is normal. The mitral valve leaflets are mildly thickened, and a mild jet of mitral regurgitation is present. Left ventricular dimensions are normal. Left ventricular systolic function is normal. The aorta and aortic valve appear normal. Right atrial and right ventricular dimensions are normal. The tricuspid valve is normal. The pulmonary artery and pulmonic valve appear normal. No shunting lesions are visualized. No pericardial effusion or cardiac masses are seen.

Tasha

INTERPRETED BY

LA - 26.7 mm  
LVIDd - 28.3 mm  
LVIDs - 17.0 mm  
FS - 39.9%  
LVOT - 0.62 m/s  
RVOT - 0.79 m/s  
TR - 3.84 m/s

Keith Blass, DVM,  
MS, DACVIM  
(Cardiology)

PATIENT

Lindy Cromer

**ASSESSMENT/RECOMMENDATIONS**

Degenerative mitral valve disease

SPECIES

This examination demonstrates mild regurgitation of blood across Lindy's mitral valve resulting from degenerative valve disease. The hemodynamic effects of the regurgitation also appear to be mild, as Lindy does not have secondary dilation of either of her left heart chambers, and her left ventricular systolic function is normal. As such, Lindy's mitral valve disease appears to be well-compensated, and her current risk for the development of clinical signs secondary to it appears to be low.

Canine

BREED

Keeshond

Lindy's cardiovascular risk for general anesthesia is only very mildly increased based on this exam, though avoidance of the medications listed in her ECG report is recommended as a precaution. Careful monitoring of Lindy's heart rhythm is recommended during the procedure.

SEX

No therapy is recommended at this stage of Lindy's mitral valve disease.

F

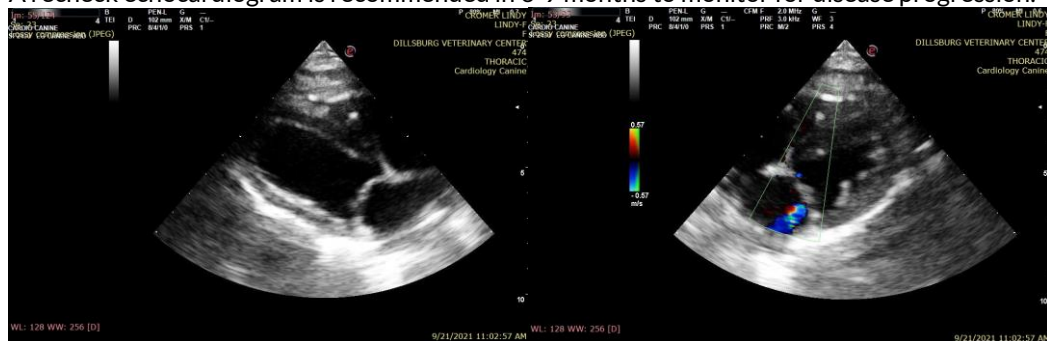A recheck echocardiogram is recommended in 6-9 months to monitor for disease progression.

AGE

6 y

WEIGHT

33 lb



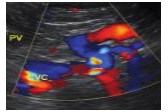
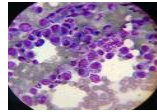
HOSPITAL NAME

Dillsburg VC

REFERRING VET

The information and recommendations provided are based on the images presented by the

Dr. Pryor



referring veterinarian. No evaluation can be communicated regarding pathology that was not visible in the image/video clips provided.

**DATE**

9/21/21

Thank you for this referral. If the clinical or image interpretation does not parallel your findings or if I can be of any further assistance please contact me.

**PERFORMED BY:**

**Keith Blass, DVM, MS, DACVIM (Cardiology)**

KeithBlass@gmail.com

631-804-5754

Tasha

**INTERPRETED BY**

Keith Blass, DVM,  
MS, DACVIM  
(Cardiology)

**PATIENT**

Lindy Cromer

**SPECIES**

Canine

**BREED**

Keeshond

**SEX**

F

**AGE**

6 y

**WEIGHT**

33 lb

**HOSPITAL NAME**

Dillsburg VC

**REFERRING VET**

Dr. Pryor